

Case Report

Use of Lipid Rescue Therapy to Reverse Immediate Central Nervous System Toxicity and Delayed Cardiovascular Collapse from Anesthetic Overdose: A Case Report and Focused Review

Adam M. Spaulding^{1*}, Samantha P. Jellinek-Cohen² and Victor Cohen³

¹Department of clinical Pharmacy-Emergency Medicine, Waterbury Hospital Health Center, USA

²Department of clinical Pharmacy-Emergency Medicine, Mount Sinai Beth Israel Medical Center, USA

³Department of Pharmacy and Emergency Medicine Maimonides Medical Center, Arnold & Marie Schwartz College of Pharmacy, USA

***Corresponding author**

Adam M. Spaulding, Clinical Pharmacy Specialist – Emergency Medicine, The Waterbury Hospital Health Center, 64 Robbins St. Waterbury, CT 06708, USA, Tel: 518-857-9631; Email: Adam.spaulding@alumni.acphs.ed

Submitted: 23 November 2014

Accepted: 05 January 2015

Published: 07 January 2015

ISSN: 2333-7079

Copyright

© 2015 Spaulding et al.

OPEN ACCESS**Keywords**

- Ropivacaine
- Local anesthetic systemic toxicity
- Lipid emulsion
- Delayed cardiovascular collapse
- Seizure

Abstract

Purpose: We report a case in which lipid therapy successfully treated both immediate central nervous system toxicity and delayed cardiovascular collapse after ropivacaine administration.

Case Details: A 54 year old female with a history of hypertension, anxiety and sleep apnea was given bilateral paravertebral blocks with a total of 45 mL 0.5% ropivacaine. Approximately 15 minutes after the block, the patient became lethargic, exhibited facial dyskinesias, and immediately progressed to a tonic/clonic seizure. Local anesthetic systemic toxicity (LAST) was suspected and a 75mL bolus of 20% lipid emulsion was administered. The seizure resolved one minute after. She later received single oral doses of lorazepam and clonazepam for anxiety, and trazodone as per her home medications. Approximately 8 hours after the seizure, the patient became bradycardic and hypotensive, refractory to atropine and fluids. Another 75mL bolus of 20% lipid emulsion was administered over 2 minutes, followed by an infusion. Within 15 minutes of the infusion, the patient became hemodynamically stable.

Discussion: Cases of ropivacaine-induced LAST successfully treated with lipid therapy exist. However, there have been no previously reported cases involving such a prolonged delay in ropivacaine toxicity. Use of the Naranjo Adverse Drug Reaction Probability Scale resulted in probable associations for ropivacaine provoking both immediate and delayed toxicities. Lipid therapy was successful in both instances, further supporting ropivacaine as the inciting agent.

Conclusion: It is important for clinicians to continuously monitor patients with LAST for delayed effects, and to not overlook the need for maintenance lipid infusions after ropivacaine toxicity.

ABBREVIATIONS

LAST: Local Anesthetic Systemic Toxicity; CNS: Central Nervous System; IVLE: Intravenous Lipid Emulsions; Bipap: Bilevel Positive Airway Pressure; ICU: Intensive Care Unit; MRI: Magnetic Resonance Image; Poct: Octanol-Water Partition Coefficient

INTRODUCTION

Cases of local anesthetic systemic toxicity (LAST) have been

reported with increased frequency over the past decade. This may be due to a higher rate of toxicity, an increased awareness of their toxic potential, or both. There is currently a plethora of reported cases available in the literature [1-8]. Table 1 summarizes some previously reported cases of LAST. One large surveillance study reported LAST occurring in 2.2/10,000 and 14.4/10,000 patients after bupivacaine and lidocaine administration, respectively [9]. LAST has been reported to occur at any time from the period immediately following the anesthetic, up to 105 minutes after administration [1,11]. Reported symptoms include bradycardia,

Table 1: Summary of Previously Reported Cases of Local Anesthetic Systemic Toxicity.

Regional Anesthetic Technique, Reference No.	Anesthetic	Dose	Reported Toxicity	Time from Anesthetic Injection to Toxicity	Lipid Therapy Treatment
Interscalene brachial plexus block ¹	0.5% bupivacaine & 1.5% mepivacaine	20 mL 20 mL	Tonic-clonic seizures, cardiovascular collapse	30 sec	100 mL bolus of 20% lipid emulsion
Axillary plexus block ²	1% ropivacaine	40 mL (400 mg)	Tonic-clonic seizures, asystolic cardiac arrest	15 min	100 mL bolus of 20% lipid emulsion continuous infusion of 10 mL/min (total 200 ml)
Femoral block & Sciatic block ³	0.5% ropivacaine & 0.5% bupivacaine	30 mL	Tonic-clonic seizures, ventricular tachycardia	20 sec	100 mL of 20% Intralipid, 400 ml of 20% Intralipid
Peritoneal dialysis catheter ⁴	2% lidocaine	1600 mg	Shortness of breath, dizziness, choking Sensation, hypertension, tachycardia	10 min	100 mL of 20% lipid emulsion
Tibial, saphenous & peroneal nerve block ⁵	0.75% ropivacaine, 0.75% ropivacaine & 0.75% ropivacaine	29 mL 5 mL 6 mL	Agitation, confusion, unconsciousness, Hypotension, bradycardia	60 min	---
Vertical infraclavicular block ⁷	0.75% ropivacaine	45 mL (5.77mg/kg)	Numbing of tongue, nausea, dizziness	20 min	---
Vertical infraclavicular block ⁷	0.75% ropivacaine	45 mL (6.38 mg/kg)	Disorientation, drowsiness, tonic-clonic seizures	20 min	---
Brachial plexus block ⁸	0.375% bupivacaine	30 mL	Convulsive seizures, asystolic cardiac arrest	Immediate	150 mL of 20% Intralipid emulsion (over 90 sec), 350 mL of Intralipid infusion over 30 mins
Peripheral nerve block ¹¹	Bupivacaine & mepivacaine	100 mg & 300 mg	Hypertension, nausea	120 min	---

Abbreviations: Min, Minutes; Sec, Second.

dizziness, ventricular tachycardia, tonic-clonic seizures, central nervous system (CNS) toxicity, cardiovascular collapse and even cardiac arrest [1-8]. Toxicity from a peripheral nerve block generally occurs by direct intravascular injection of therapeutic doses or systemic absorption of a toxic dose of local anesthetic [10]. It is therefore imperative to quickly recognize the event as LAST and initiate proper therapy.

Animal research as well as case reports have offered strong evidence for the use of intravenous lipid emulsions (IVLE) in patients experiencing CNS toxicity and cardiovascular collapse from local-anesthetic overdose [1-8,12-14]. Furthermore, *invitro* studies have demonstrated the capacity of lipids to successfully uptake bupivacaine from an aqueous media [12,13,15-17]. Based on this evidence, IVLE has rapidly evolved to become a first-line therapy for LAST [18,19]. However, pharmacologic considerations regarding individualized dosing, timing of administration and the use of repeated boluses or continuous infusions are still evolving.

We present a unique case of a patient with immediate CNS toxicity, followed by a delayed cardiovascular collapse, which occurred approximately 8 hours after ropivacaine administration. Lipid rescue therapy was successfully utilized for both episodes. Our case illustrates the importance of closely monitoring patients with LAST for the possibility of delayed cardiovascular sequelae. A summary of previously reported cases, current recommendations for management, pharmacokinetics, and a

discussion of the therapeutic utility of IVLE therapy for LAST will be also be reviewed.

CASE PRESENTATION

We report the case of a petite (50 kg, 4'11"), 54 year old female admitted to same day surgery for an elective bilateral breast reduction. Her past medical history includes hypertension, anxiety and sleep apnea. Her home medications include hydrochlorothiazide/triamterene 25 mg-37.5 mg orally once daily, clonazepam 0.25 mg orally three times daily as needed, trazodone 50 mg orally at bedtime, famotidine 20 mg orally twice daily and a multivitamin orally daily. There was no report of bilevel positive airway pressure (*BiPAP*) use at home. Local anesthesia was achieved with bilateral paravertebral blocks of 0.5% ropivacaine. A total of 45 mL was given with incremental negative aspirations every 5 mL. Approximately 15 minutes after the block, the patient became lethargic, exhibited facial dyskinesias with rigidity, and within seconds eventually progressed to a tonic/clonic seizure. LAST was suspected due to the temporal nature of the seizure and a 75 mL bolus of 20% lipid emulsion was immediately administered over 2 minutes. No benzodiazepines were given. The seizure resolved approximately one minute after administration of the lipid emulsion. Throughout the event, the patient remained hemodynamically stable. After a brief postictal state, the patient awakened and was oriented to name, place, date and birth date. No focal motor deficits were

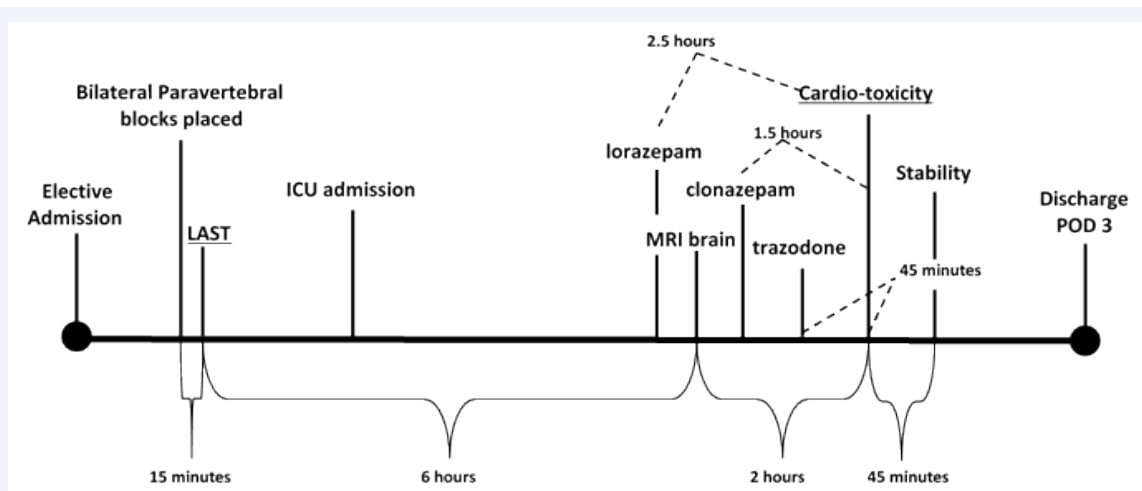


Figure 1 Schematic Timeline of the Course of Patient Toxicity.

Note: Admission and discharge are not scaled to time.

Abbreviations: LAST: Local-Anesthetic Systemic Toxicity; ICU: Intensive Care Unit; MRI: Magnetic Resonance Image; POD: Post-Operative Day

Table 2: Pharmacokinetic Comparison Between Bupivacaine and Ropivacaine in Adults [14,33].

Parameter	Bupivacaine	Ropivacaine
Duration (single dose)	2-9 hours (dose/route dependent)	3-15 hours (dose/route dependent)
Protein binding	95%	94%
Vd	73L	41L
Metabolism	Hepatic; forms inactive metabolite pipercoloxylidine (PPX)	Hepatic via CYP1A2 to inactive metabolites
Poct	3.4	2.9

Abbreviations: Poct: Octanol-Water Partition Coefficient - Indicates Lipophilicity, A Higher Score Denotes Increased Lipophilicity; Vd: Volume Of Distribution

Table 3: Current Considerations for Dosing and Management during Lipid Resuscitation [18,19].

Current Considerations for Dosing and Management During Lipid Resuscitation
<ul style="list-style-type: none"> • Consider the use of a protocolized checklist • Intralipid 20% lipid emulsion most widely used • Bolus dose: 1.5mL/kg given over about 1 minute (~100ml for 70kg adult) • Infusion: 0.25-0.5mL/kg/min immediately following bolus dose (~18-35mL/min) • Continue infusion until vital signs recover and for at least 10 minutes following vital sign recovery • Repeated bolus doses and/or increasing the infusion rate (0.5mL/kg/min) is advised if there are signs of persistent toxicity • The upper dose limit for lipid emulsion therapy is 10 mL/kg over 30 minutes • During cardiotoxicity with low output states, high quality CPR remains an integral component of lipid resuscitation • Prolonged monitoring (> 12 hours) is recommended after any signs of systemic local anesthetic toxicity, since cardiovascular depression due to local anesthetics can persist or recur after treatment.

noted and the patient had no recall of the event. The patient was admitted to the intensive care unit (ICU) for further monitoring of anticipatory cardiovascular collapse. While in the ICU, she received one dose of lorazepam 1 mg orally 30 minutes prior to a magnetic resonance image (MRI) of the brain. During her ICU stay, she also received clonazepam 1mg orally, followed later by a dose of trazodone 50mg orally from her documented home medication list. It was eventually discovered by the clinical pharmacist that the patient had stopped taking trazodone a few months prior due to excessive sedation. Approximately 8 hours after the seizure and after returning to the unit from an unimpressive MRI, the patient became bradycardic, with a heart rate in the high 30's and hypotensive, with a systolic blood pressure fluctuating from 60-80 mmHg. She was very lethargic, but arousable and oriented to time and place. Signs of difficult ventilation were noted and the patient was initiated on BiPAP. A dose of atropine 1 mg intravenous push was given, along with a liter bolus of normal saline with no response. Urine output was adequate, and all other laboratory parameters were within normal range. The differential diagnosis included a delayed effect from the local anesthetic. Therefore, another 75 mL bolus of 20% lipid emulsion was given over 2 minutes, followed by an infusion of 0.25mL/kg/min over 1 hour dosed by the clinical pharmacist. Within 15 minutes of starting the lipid infusion, the patient's heart rate rose into the mid 50's and systolic blood pressure gradually normalized to the 130's. The hemodynamic stabilization persisted throughout the duration of the lipid infusion. There were no observed adverse effects of the lipid emulsion therapy. The patient remained stable for the duration of her hospital stay and was successfully discharged on hospital day four. Refer to (Figure 1) for a timeline depicting the course of patient toxicity, as well as drug administration.

DISCUSSION

We present the first case in which a delayed cardiovascular collapse was suspected approximately 8 hours after ropivacaine

administration. However, as the patient was given lorazepam, clonazepam and trazodone prior to this episode, it is important to discern whether this episode could be attributed to the medications given or whether it was a continuation of LAST. Previously reported adverse effects of trazodone include drowsiness, cardiac arrhythmias, including QT prolongation, and mild hypotension [20]. However, these side effects have typically been reported in patients given toxic doses. Maximum tolerated doses in the elderly have been demonstrated to range from 300-400 mg/day [20]; our patient received 50 mg. Thus, trazodone toxicity in the setting of the given dosage is unlikely, especially since the patient had been previously exposed to this dose of trazodone at home.

Multiple studies have demonstrated that lorazepam has a delayed peak plasma concentration, and a longer time to pass into brain tissue; shown to likely be the result of low lipophilicity [21-27]. Both lorazepam and clonazepam have been demonstrated to have oil-water partition coefficients of 0.99 and 1.46, respectively; another indication of their lower lipophilicity as compared to ropivacaine or bupivacaine (Table 2) [28]. Moreover, while ropivacaine-induced LAST has been successfully treated with IVLE, there are no such findings regarding benzodiazepines or trazodone [5,7]. Additionally, the benzodiazepines were not given in toxically high doses in our case, and the cardiovascular collapse was successfully treated with IVLE. Although a synergistic affect between the medications administered is always possible, given that lipid therapy resolved the collapse, we find this to be a less likely scenario. Moreover, our patient received 4.3mg/kg of ropivacaine, while recommendations have been made not to exceed 3mg/kg [10,30]. Taken together, we have evidence to suggest that the cardiovascular collapse was likely a component of ropivacaine-induced LAST. A plausible explanation for this event may be due to the relatively hydrophilic nature of ropivacaine, and the possibility of a delayed toxic effect due to a slow redistribution to and from tissues. Furthermore ropivacaine has an octanol-water partition coefficient (poc_t) of 2.9, denoting a lower lipophilicity relative to bupivacaine (Table 2) [14,33].

The Naranjo Adverse Drug Reaction Probability Scale is a commonly used questionnaire which determines the probability that an administered drug is the cause of an adverse event rather than another variable.²⁹ The scale ranges from zero to greater than 9; zero representing the lowest probability of the drug causing the adverse event, and 9 representing a high likelihood. Both the seizure activity and the late-onset hemodynamic instability resulted in a score of 6, consistent with probable associations. Each toxic event received one point for having previously published reports available documenting similar reactions [1-8]. Further, both events received two points because they occurred sometime after administration of the suspected drug. As for the delayed toxicity, events similar to ours have been sparsely documented in case reports from both Chazalon et al and Schwartz et al, with presumed LAST at 60 and 120 minutes after appropriate doses of peripheral nerve blocks, respectively [5,11]. Although a delayed onset of the magnitude as in our case has not been previously reported, this may be because toxic doses

of a peripheral nerve block were used. Moreover, because both the seizure and the cardiovascular collapse improved rapidly after administration of IVLE, another point was granted for this temporal association. Finally, two more points were assigned, as there appear to be no other causes within the context of this case that could have independently caused either of these reactions.

Safe dosing of ropivacaine

Although there is no well-established maximum dose of ropivacaine, two previously published papers have warned against using doses that exceed 3mg/kg [10,30]. However, others report toxicity at 3mg/kg, and yet others advocate for a relative maximum of 300mg, regardless of weight [6,7]. Nevertheless, current recommendations regarding maximum dosages are not evidence based, but it appears that individualized weight-based dosing of ropivacaine is the safest method. The patient described in our case received 4.3mg/kg, for a total dose of 225mg of ropivacaine. Yang et al reported patient cases similar to ours; two patients weighing about 50kg [7]. Each patient received high dose ropivacaine (45ml of 0.75%), which was well over 3mg/kg for both (5.77mg/kg in the first patient and 6.38mg/kg in the second patient). Additionally, both cases involved a delay of over 20 minutes before symptoms ensued.

Pharmacokinetics and mechanisms of Action

The majority of existing case reports describing local-anesthetic toxicity are secondary to bupivacaine [1,3,8]. Despite the current theory that ropivacaine entails a reduction in the risk of cardiovascular toxicity relative to older amide-type anesthetics [31], there is emerging literature documenting ropivacaine as the inciting agent for LAST. This is concerning as the toxic effects of ropivacaine may be less responsive to lipid rescue therapy due to its reduced lipophilicity as compared to bupivacaine [32]. (Table 2) outlines a comparison of pharmacokinetic parameters between ropivacaine and bupivacaine, which may assist the clinician in anticipating differences in the time course and presentation of toxicity among these agents [2,5-7]. The proposed primary mechanism for the therapeutic effect of lipids has focused on the "lipid sink" theory, whereby the lipophilic nature of anesthetics are preferentially partitioned into a lipemic plasma compartment caused by the lipid emulsion, thereby sparing tissues [1]. Recent evidence points to a concurrent metabolic effect; Mottram et al demonstrated the ability of common fatty acids to attenuate bupivacaine-induced cardiac sodium channel blockade [14-15,33]. This suggests that IVLE has a direct pharmacodynamic effect in the reversal of local-anesthetic toxicity.

Recommendations for management

Current guidelines by the American Society of Regional Anesthesia and Pain Medicine advocate for the stocking and rapid acquisition of IVLE therapy in any immediate setting where local and regional anesthetic techniques occur [18]. The guidelines also call for the availability of continued dosing, either by subsequent bolus doses and/or initiation of a lipid infusion. (Table 3) summarizes currently accepted recommendations for lipid resuscitation. Our case, as well as the one by McCutchen et

al, serves as testament to these recommendations; in both cases, continued therapy with a lipid infusion was necessary to prevent worsening or presumptive cardiovascular toxicity [3].

CONCLUSION

Although IVLE therapy has been utilized to reduce the toxic effects of LAST for some time, the mechanism underlying its therapeutic benefit is just now being further elucidated. Case reports remain an important source of evidence, which add to the growing body of literature for IVLE therapy used for reversal of LAST. We summarize the first case of delayed cardiovascular toxicity with ropivacaine occurring after 8 hours. Therefore, the need for continuous monitoring of these patients after stabilization, and consideration for repeated dosing strategies, seems vital for patient safety.

REFERENCES

1. Rosenblatt MA, Abel M, Fischer GW, Itzkovich CJ, Eisenkraft JB. Successful use of a 20% lipid emulsion to resuscitate a patient after a presumed bupivacaine-related cardiac arrest. *Anesthesiology*. 2006; 105: 217-218.
2. Litz RJ, Popp M, Stehr SN, Koch T. Successful resuscitation of a patient with ropivacaine-induced asystole after axillary plexus block using lipid infusion. *Anaesthesia*. 2006; 61: 800-801.
3. McCutchen T, Gerancher JC. Early intralipid therapy may have prevented bupivacaine-associated cardiac arrest. *Reg Anesth Pain Med*. 2008; 33: 178-180.
4. Lange DB, Schwartz D, DaRoza G, Gair R. Use of intravenous lipid emulsion to reverse central nervous system toxicity of an iatrogenic local anesthetic overdose in a patient on peritoneal dialysis. *Ann Pharmacother*. 2012; 46: e37.
5. Chazalon P, Tourtier JP, Villevielle T, Giraud D, Saissy JM, Mion G, et al. Ropivacaine-induced cardiac arrest after peripheral nerve block: successful resuscitation. *Anesthesiology*. 2003; 99: 1449-1451.
6. Puri A, Harbell MW, Aleshi P. Intravascular femoral nerve catheter results in CNS toxicity with low-dose ropivacaine. *Reg Anesth Pain Med*. (abstract A200). *Reg Anesth Pain Med*. 2013.
7. Yang CW, Kang PS, Kwon HU, Lim DJ. High dose ropivacaine-induced toxicity after infraclavicular block. *Korean J Anesthesiol*. 2012; 62: 96-97.
8. Marwick PC, Levin AI, Coetzee AR. Recurrence of cardiotoxicity after lipid rescue from bupivacaine-induced cardiac arrest. *Anesth Analg*. 2009; 108: 1344-1346.
9. Auroy Y, Benhamou D, Bargues L, Ecoffey C, Falissard B, Mercier FJ, et al. Major complications of regional anesthesia in France: The SOS Regional Anesthesia Hotline Service. *Anesthesiology*. 2002; 97: 1274-1280.
10. Cox B, Durieux ME, Marcus MA. Toxicity of local anaesthetics. *Best Pract Res Clin Anaesthesiol*. 2003; 17: 111-136.
11. Schwartz D, VadeBoncouer T, Weinberg G. Was case report a case of unrecognized local anesthetic toxicity? *Anesth Analg*. 2003; 96: 1844-1845.
12. Weinberg GL, Ripper R, Murphy P, Edelman LB, Hoffman W, Strichartz G, et al. Lipid infusion accelerates removal of bupivacaine and recovery from bupivacaine toxicity in the isolated rat heart. *Reg Anesth Pain Med*. 2006; 31: 296-303.
13. Niiya T, Litonius E, Petäjä L, Neuvonen PJ, Rosenberg PH. Intravenous lipid emulsion sequesters amiodarone in plasma and eliminates its hypotensive action in pigs. *Ann Emerg Med*. 2010; 56: 402-408.
14. Partownavid P, Umar S, Li J, Rahman S, Eghbali M. Fatty-acid oxidation and calcium homeostasis are involved in the rescue of bupivacaine-induced cardiotoxicity by lipid emulsion in rats. *Crit Care Med*. 2012; 40: 2431-2437.
15. Kuo I, Akpa BS. Validity of the lipid sink as a mechanism for the reversal of local anesthetic systemic toxicity: a physiologically based pharmacokinetic model study. *Anesthesiology*. 2013; 118: 1350-1361.
16. Mazoit JX, Le Guen R, Beloeil H, Benhamou D. Binding of long-lasting local anesthetics to lipid emulsions. *Anesthesiology*. 2009; 110: 380-386.
17. Weinberg G, Lin B, Zheng S, Di Gregorio G, Hiller D, Ripper R, et al. Partitioning effect in lipid resuscitation: further evidence for the lipid sink. *Crit Care Med*. 2010; 38: 2268-2269.
18. Neal JM, Mulroy MF, Weinberg GL. American Society of Regional Anesthesia and Pain Medicine . American Society of Regional Anesthesia and Pain Medicine checklist for managing local anesthetic systemic toxicity: 2012 version. *Reg Anesth Pain Med*. 2012; 37: 16-18.
19. ASRA recommendations on systemic toxicity of local anesthetics. American Academy of Orthopedic Surgeons, 2008.
20. Haria M, Fitton A, McTavish D. Trazodone. A review of its pharmacology, therapeutic use in depression and therapeutic potential in other disorders. *Drugs Aging*. 1994; 4: 331-355.
21. Greenblatt DJ, von Moltke LL, Ehrenberg BL, Harmatz JS, Corbett KE, Wallace DW, et al. Kinetics and dynamics of lorazepam during and after continuous intravenous infusion. *Crit Care Med*. 2000; 28: 2750-2757.
22. Greenblatt DJ, Ehrenberg BL, Gunderman J, Scavone JM, Tai NT, Harmatz JS, et al. Kinetic and dynamic study of intravenous lorazepam: comparison with intravenous diazepam. *J Pharmacol Exp Ther*. 1989; 250: 134-140.
23. Greenblatt DJ, Sethy VH. Benzodiazepine concentrations in brain directly reflect receptor occupancy: studies of diazepam, lorazepam, and oxazepam. *Psychopharmacology (Berl)*. 1990; 102: 373-378.
24. Walton NY, Treiman DM. Lorazepam treatment of experimental status epilepticus in the rat: relevance to clinical practice. *Neurology*. 1990; 40: 990-994.
25. Jack ML, Colburn WA, Spirt NM, Bautz G, Zanko M, Horst WD, et al. A pharmacokinetic/pharmacodynamic/receptor binding model to predict the onset and duration of pharmacological activity of the benzodiazepines. *Prog Neuropsychopharmacol Biol Psychiatry*. 1983; 7: 629-635.
26. Sethy VH, Francis JW, Elfring G. Onset and duration of action of benzodiazepines as determined by inhibition of (3H)-flunitrazepam binding. *Drug Des Res*. 1987; 10:117-121.
27. Arendt RM, Greenblatt DJ, deJong RH, Bonin JD, Abernethy DR, Ehrenberg BL, et al. In vitro correlates of benzodiazepine cerebrospinal fluid uptake, pharmacodynamic action and peripheral distribution. *J Pharmacol Exp Ther*. 1983; 227: 98-106.
28. Sila-on W, Vardhanabhuti N, Ongpipattanakul B, Kulvanich P. Influence of incorporation methods on partitioning behavior of lipophilic drugs into various phases of a parenteral lipid emulsion. *AAPS PharmSciTech*. 2008; 9: 684-692.
29. Naranjo CA, Busto U, Sellers EM, Sandor P, Ruiz I, Roberts EA, et al. A method for estimating the probability of adverse drug reactions. *Clin Pharmacol Ther*. 1981; 30: 239-245.

30. Rosenberg PH, Veering BT, Urmey WF. Maximum recommended doses of local anesthetics: a multifactorial concept. *Reg Anesth Pain Med.* 2004; 29: 564-575.
31. Kuthiala G, Chaudhary G. Ropivacaine: A review of its pharmacology and clinical use. *Indian J Anaesth.* 2011; 55: 104-110.
32. Mazoit JX, Le Guen R, Beloeil H, Benhamou D. Binding of long-lasting local anesthetics to lipid emulsions. *Anesthesiology.* 2009; 110: 380-386.
33. Mottram AR, Valdivia CR, Makielski JC. Fatty acids antagonize bupivacaine-induced I(Na) blockade. *Clin Toxicol (Phila).* 2011; 49: 729-733.

Cite this article

Spaulding AM, Jellinek-Cohen SP, Cohen V (2015) Use of Lipid Rescue Therapy to Reverse Immediate Central Nervous System Toxicity and Delayed Cardiovascular Collapse from Anesthetic Overdose: A Case Report and Focused Review. *J Pharmacol Clin Toxicol* 3(1):1041.